

# V9-2 PureWave transducer assists in the diagnosis of a severe fetal intracranial abnormality

V9-2 PureWave volume transducer

### Category

Fetal Central Nervous System (CNS)

### Author

Michael S. Ruma, MD, MPH  
Maternal-Fetal Medicine  
Perinatal Associates of New Mexico  
Albuquerque, NM

### Overview

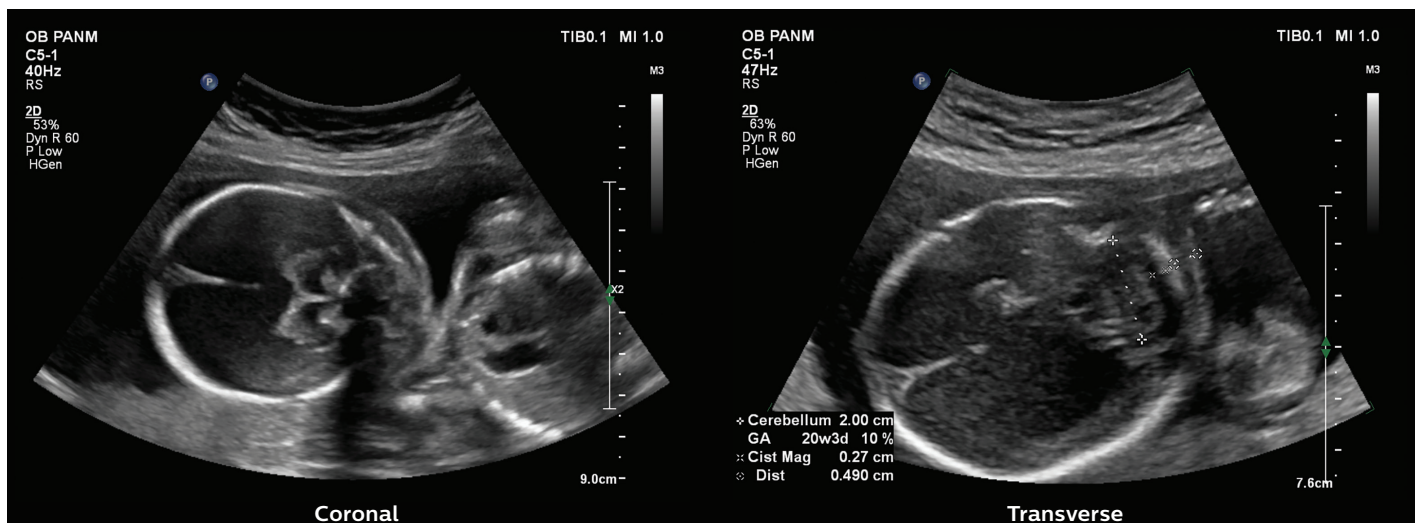
Intracranial abnormalities or malformations of the central nervous system (CNS) are one of the most common types of major fetal anomalies.<sup>1</sup> Antenatal diagnosis of a cerebral malformation occurs in approximately 1% of all births.<sup>2</sup> Advancements in prenatal diagnostic ultrasound over the last several decades allow for the determination of gestational age, number of fetuses, type of multiple gestation, pregnancy viability, placental location and the diagnosis of minor and major fetal anomalies.

2D ultrasound is routinely the initial modality utilized in the evaluation and prenatal diagnosis of fetal intracranial anomalies. However, as technology and its ease of use progresses, 3D and 4D ultrasound now play a larger role in the diagnosis of CNS abnormalities and may help, in particular, with the counseling and the patient's understanding of the diagnosis. While a variety of intracranial abnormalities are commonly noted on 2D ultrasound, the prenatal diagnosis

of these malformations remains challenging. Differentiating the wide variety of diagnoses present in the fetal brain is incredibly important for the clinician involved with counseling the parents, as different anomalies portend a broadly ranging prognosis and outcome for the unborn child.<sup>2</sup>

### Patient history

A 28-year-old gravida 1 para 0 pregnant patient at 21 3/7 weeks gestation presented to Perinatal Associates of New Mexico (PANM) for routine obstetric ultrasound screening evaluation. An obstetric ultrasound was conducted at our practice utilizing a Philips EPIQ Elite ultrasound system with both the C5-1 curvilinear and V9-2 PureWave volume transducers. The ultrasound evaluation demonstrated a breech male fetus with a normal estimated fetal weight. The fetal anatomic survey identified a severe intracranial abnormality with no additional fetal abnormalities (**Figure 1**).



**Figure 1** C5-1 transducer images of fetal intracranial abnormality.

The V9-2 curvilinear volume transducer was used to obtain additional 2D images and 3D volumes to provide a surface-rendered image for patient counseling (Figure 2).

### Research protocol

The patient was enrolled in a clinical evaluation study of the V9-2 PureWave volume transducer which was ongoing at the time of her consultation at our practice. Utilizing the V9-2 PureWave volume transducer on the Philips EPIQ Elite ultrasound system, additional imaging was performed, with particular focus on the fetal intracranial anatomy. TrueVue 3D imaging, designed to enhance the imaging of a 3D volume with an internal virtual light source, was utilized to assess the fetal intracranial anatomy.

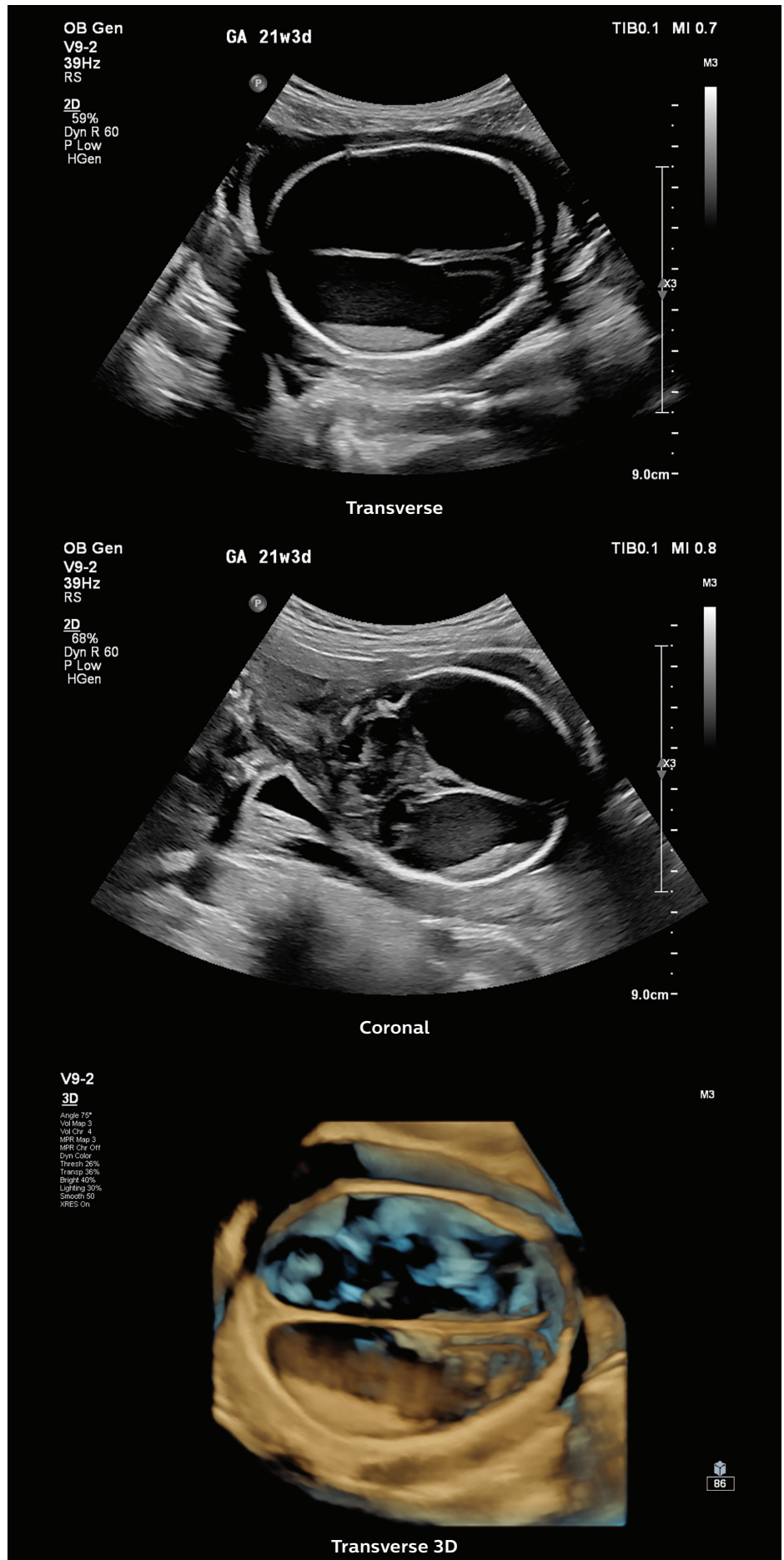
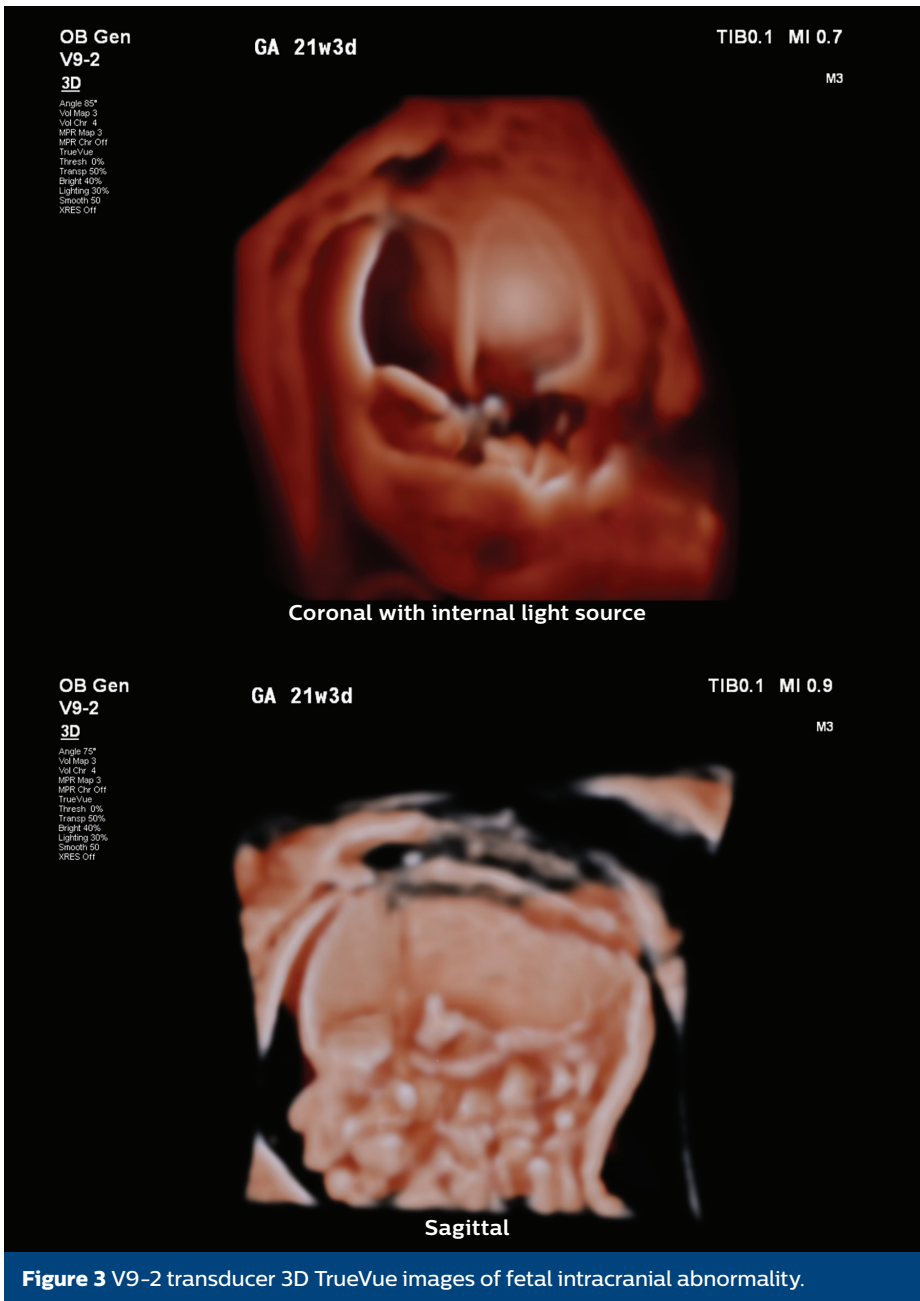


Figure 2 V9-2 transducer images of fetal intracranial abnormality.



## Findings

Initial 2D imaging using the C5-1 transducer demonstrated a markedly abnormal fetal brain. The findings based on evaluation solely with the C5-1 transducer were concerning for severe bilateral ventriculomegaly. With the use of the V9-2 transducer, additional intracranial abnormalities were noted, including the finding of dependent, echogenic debris in the far-field cerebral hemisphere, and provided evidence to support the diagnosis of hydranencephaly. Without changing transducers, a 3D volume was obtained with the V9-2 transducer (**Figure 2**). Using the different surface rendering modes, the fetal intracranial abnormality was explored while utilizing the internal virtual light source. Manipulation of the 3-D volume and further investigation of the imaging substantiated the diagnosis (**Figure 3**). The patient was informed of the findings of fetal hydranencephaly, including a discussion regarding the lack of specific treatment and the poor prognosis of this diagnosis.

**Figure 3** V9-2 transducer 3D TrueVue images of fetal intracranial abnormality.

## Conclusion

The utility of ultrasound remains formidable as a frontline, low-cost imaging modality and continues to demonstrate its important role in the prenatal diagnosis of fetal anomalies. Each decade brings remarkable advancements in ultrasound technology which continue to change the way clinicians evaluate and diagnose many fetal abnormalities. With state-of-the-art transducer technology such as the V9-2 PureWave volume transducer, our dependence on 2D imaging to evaluate fetal anatomy is decreasing as clinicians at PANM become confident in applying 3D volume rendering to a variety of different fetal diagnoses.

In this patient's case, the fetal diagnosis was not initially accurate with use of solely 2D imaging from the C5-1 transducer. Our diagnosis of severe bilateral ventriculomegaly was incorrect because the dependent, echogenic debris was not visible on initial imaging. The higher frequency of the V9-2 PureWave transducer allowed for superior imaging and the ability to detect the liquefied brain and blood, a characteristic sonographic feature of hydranencephaly.

In the last decade, fetal magnetic resonance imaging (MRI) has been utilized increasingly to evaluate fetal intracranial anomalies.<sup>1</sup> Fetal MRI may be particularly useful to assess disorders of gray and white matter, intraventricular bleeding and migration disorders.<sup>2</sup> However, with innovative tools such as the V9-2 PureWave volume transducer and TrueVue for interpretation of fetal 3D volumes, the need for fetal MRI and its associated expense may decrease over time. In this case, the fetal diagnosis was made with greater accuracy solely using advanced ultrasound transducers and novel PureWave technology, which provided the clinician and the patient a greater degree of confidence in the true diagnosis of hydranencephaly in the fetus.

## Reference

- 1 The International Society of Ultrasound in Obstetrics and Gynecology. Sonographic examination of the fetal central nervous system: guidelines for performing the "basic examination" and the "fetal neurosonogram". *Ultrasound Obstet Gynecol.* 2007;29:109–16.
- 2 De Keersmaecker B, Claus F, De Catte L. Imaging the fetal central nervous system. *Facts Views Vis OBGYN.* 2011;3:135–49.

Results from case studies are not predictive of results in other cases. Results in other cases may vary.

